

MANAGEMENT OF PERFORATIONS

DR. SIJU JACOB

INTRODUCTION

Perforations of the crown and root are iatrogenic errors that may occur occasionally during Endodontic therapy. This article presents two case reports of perforations and their clinical management.

CASE 1: PERFORATION REPAIR IN MAXILLARY FIRST MOLAR

A 60 year old female patient reported with severe pain and inability to chew on an endodontically treated maxillary right first molar. The patient informed that the tooth had been endodontically treated twice over the last six months and continued to be symptomatic.

Clinical examination revealed tenderness on palpation of the maxillary right first molar and buccal soft tissue. Periodontal findings were within normal limits. A straight angled radiograph suggested a missed distal canal (**Figure 1a**) where as an of-angled radiograph showed what appeared to be 3 canals filled (**Figure 1b**). The treatment options were discussed with the patient and a decision was made to re-access and re-evaluate the tooth for further treatment.

After anesthesia and rubber dam application, the old composite access cavity restoration was carefully removed using burs and ultrasonics under the surgical operating microscope (**Figures 2a, 2b**). Examination under magnification revealed two filled canals - the mesio-buccal and palatal - and a missed distal canal. A distal perforation was seen wrongly treated and filled as a third canal (**Figures 3a, 3b**).

Gutta percha was removed from the perforation and the filled canals. The perforation was repaired with MTA (**Figure 4a**). All canals were shaped, cleaned and calcium hydroxide placed (**Figure 4b**). Patient was recalled after two weeks. Patient reported

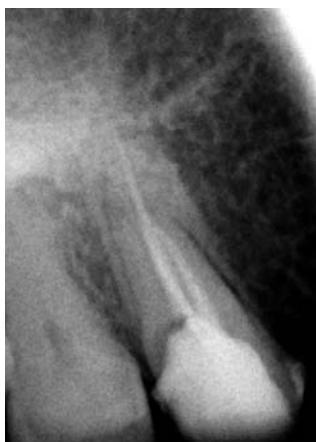

FIG 1a: Straight angled radiograph suggests a missed distal canal

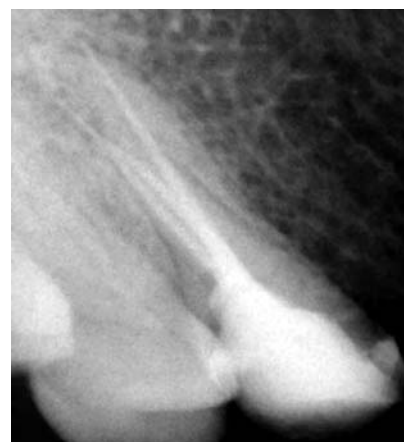

FIG 1b: Off-angled radiograph shows 3 filled canals

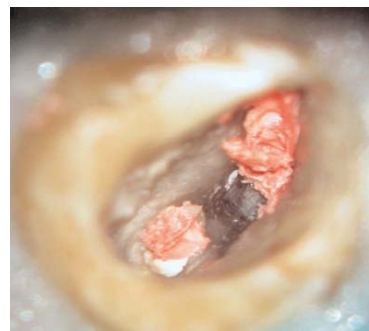
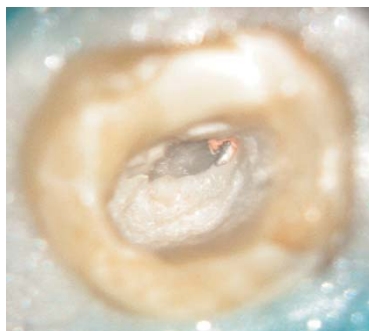


FIG 2a & 2b: Access cavity restoration removed carefully under the microscope using burs and ultrasonics

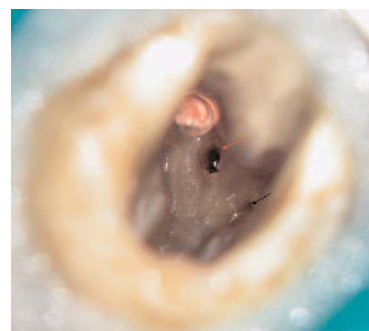
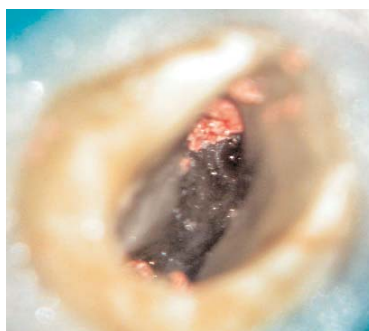


FIG 3a & 3b: Orange arrow shows perforation from which gutta percha was removed. Black arrow shows the missed distal canal.

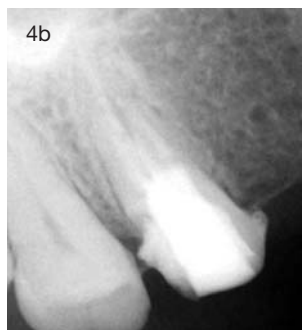
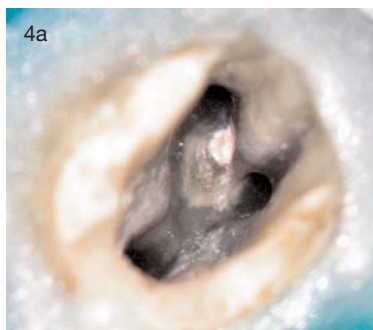

FIG 4a: Perforation repaired with MTA

FIG 4b: Canals filled with calcium hydroxide

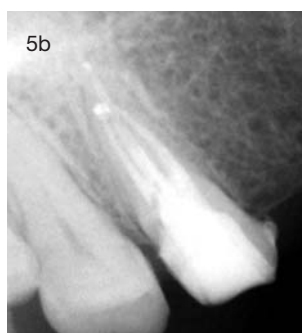
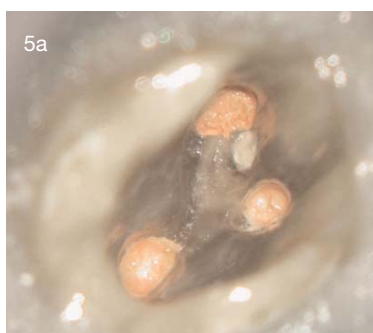
FIG 5a & 5b: Canals obturated with gutta percha. Access sealed with composite resin

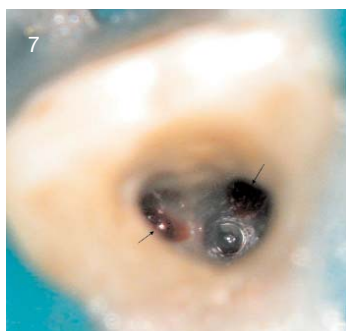
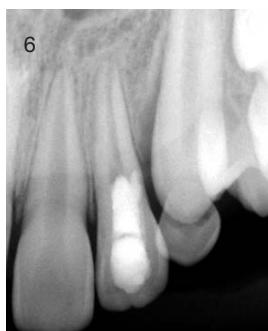
FIG 6: Pre-operative radiograph showing patent canal and evidence of perforation

FIG 7: Black arrows denote the two perforations

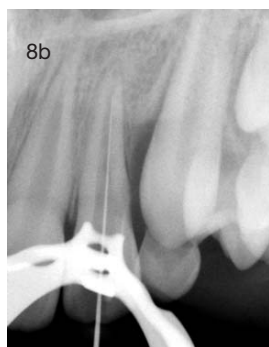
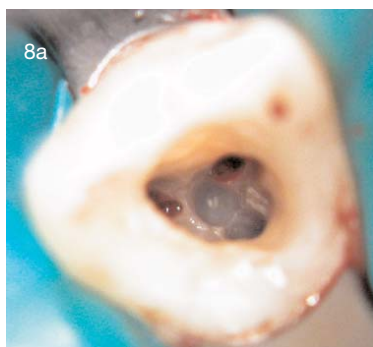


FIG 8a: Actual canal located palatal to the perforations

FIG 8b: Wire film confirms canal location

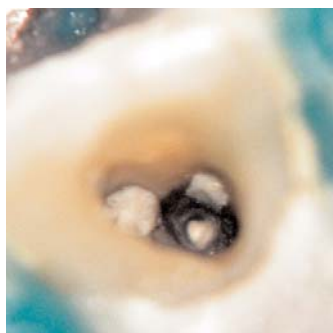

FIG 9: Perforations repaired with MTA

asymptomatic and all canals were obturated with Gutta percha and Ah plus sealer in warm vertical condensation technique (Figures 5a, 5b). The Access cavity was sealed with composite resin and patient was referred for a new crown.

CASE 2: MULTIPLE PERFORATION REPAIR IN MAXILLARY LATERAL INCISOR

An eleven year old female patient was referred for Micro-endodontics. The referral accompanied the patient and gave a history of inability to locate the canal in a maxillary lateral incisor tooth. The referral informed that in a quest to locate the canal, she had inadvertently perforated the tooth.

Clinical examination revealed severe tenderness to palpation in the left maxillary lateral incisor tooth and labial soft tissue. Radiographic examination revealed a patent canal and evidence of perforation (Figure 6). Treatment options were discussed with the patient's parents and a decision was made to re-access and re-evaluate the tooth for further treatment.

After anesthesia and rubber dam application, the temporary filling was removed and the access cavity was observed under the surgical microscope. Two perforations were observed (Figure 7). The actual canal was located palatal to where the perforations were present (Figure 8a, 8b). The actual canal was cleaned, shaped and filled with calcium hydroxide. The perforations were sealed with MTA (Figure 9). The patient was recalled after 10 days. The MTA was verified to have set and sealed the perforations and the canal was obturated with gutta percha in warm vertical condensation (Figure 10a, 10b). The Access cavity was sealed with glass ionomer cement injected through a centrix needle (Figure 11).

DISCUSSION

Perforations are iatrogenic errors that may occur during endodontic therapy. They may be differentiated from canals by three ways:

Radiographs: straight and off-angled radiographs give a clue as to whether the file is in the canal or in a perforation.

Apex locator: Apex locators are useful in diagnosis of perforations. Persistent readings indicating that the file is beyond the apex even when it is only a few millimeters into the orifice can give a clue on the possi-

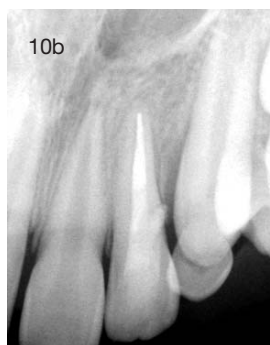
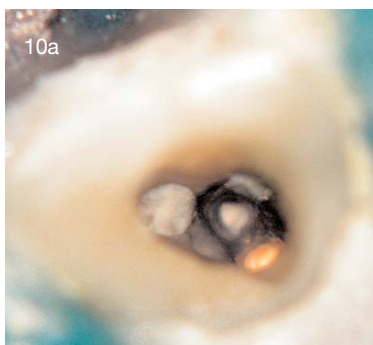

FIG 10a: Chamber photograph showing obturation of the canal with gutta percha and perforation repair with MTA

FIG 10b: Post obturation radiograph

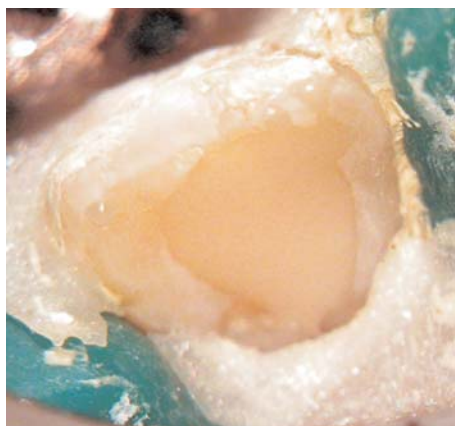


FIG 11: Access cavity sealed with glass ionomer cement

placing MTA in patients. Improper placement can occasionally result in MTA not setting completely. The setting has to be verified in the recall visit.

CONCLUSION

Perforations are inadvertent errors that may occur during endodontic therapy. Proper magnification with the surgical microscope and repair with MTA can give predictable results in perforation management. Prevention, however, is better than cure and the operator can avoid perforations by having a thorough knowledge about root canal anatomy, radiographic clues and common variations that can occur in individual teeth.

bility of a perforation.

Excessive bleeding: Perforations bleed profusely. Persistent, continuous bleeding can alert the operator to a possibility of perforation.

A combination of the 3 methods described above may be used to diagnose perforations.

Proper magnification helps in all aspects of Endodontic therapy. A Surgical microscope is useful in identifying and repairing perforations and also in locating missed anatomy. Thorough knowledge about canal anatomy helps the operator avoid perforations. For example, as seen in the second case described, when treating maxillary Incisors, one should be aware of how these teeth can be labially proclined. One must therefore make a conscious effort to tilt the bur palatally as the access moves apical. This will help maintain the bur along the long axis of the tooth.

MTA is recognized as the best material available today to seal perforations. It has excellent sealing properties and has been well researched. However, it is not an easy material to manipulate and place. The operator has to train on extracted teeth before

About the AUTHOR



Dr. Siju Jacob completed his BDS from Bangalore Institute of Dental Sciences and his MDS in Endodontics from Saveetha Dental College, Chennai. Dr. Siju is the founder of "The Root Canal Clinic", an Exclusive

Endodontic practice. He pioneered Microscopic Endodontics in Bangalore and manages a center for Micro-Endodontic training at Bangalore. In addition, he consults in Andaman and Nicobar islands. Dr. Siju is passionate about educating Dentists on advancements in Endodontics. He has trained over 10,000 dentists in CDE programmes conducted over the last decade. He has lectured extensively at numerous conferences, has several publications to his credit and has contributed to two Prominent Endodontic textbooks. He is a reviewer for the Journal of Conservative Dentistry. He can be contacted through his website www.rootcanalclinic.com